

2014

Altered Tendon Characteristics and Mechanical Properties Associated with Insertional Achilles Tendinopathy

Ruth L. Chimenti

Adolph S. Flemister

Joshua Tome

James M. McMahan

Marie A. Flannery

See next page for additional authors

Follow this and additional works at: https://digitalcommons.georgefox.edu/pt_fac

 Part of the [Physical Therapy Commons](#)

Recommended Citation

Chimenti, Ruth L.; Flemister, Adolph S.; Tome, Joshua; McMahan, James M.; Flannery, Marie A.; Xue, Ying; and Houck, Jeff R., "Altered Tendon Characteristics and Mechanical Properties Associated with Insertional Achilles Tendinopathy" (2014). *Faculty Publications - School of Physical Therapy*. 51.

https://digitalcommons.georgefox.edu/pt_fac/51

This Article is brought to you for free and open access by the School of Physical Therapy at Digital Commons @ George Fox University. It has been accepted for inclusion in Faculty Publications - School of Physical Therapy by an authorized administrator of Digital Commons @ George Fox University. For more information, please contact arolfe@georgefox.edu.

Authors

Ruth L. Chimenti, Adolph S. Flemister, Joshua Tome, James M. McMahon, Marie A. Flannery, Ying Xue, and Jeff R. Houck

Altered Tendon Characteristics and Mechanical Properties Associated With Insertional Achilles Tendinopathy

Insertional Achilles tendinopathy (IAT) is a debilitating condition that is challenging to treat clinically. The disability associated with IAT interferes with daily weight-bearing activities. After failure of conservative care, patients seeking operative care reported that pain limited their ability to walk and to work full time.¹⁵ While the standard of care includes a trial of physical therapy, approximately half of patients with IAT progress to having surgery.²⁶ Surgery is costly in terms of financial resources,

time off work due to weight-bearing restrictions, and risk of complications.^{15,24} Moreover, even a year after surgery, many patients continue to report some pain and functional limitations.^{15,24} Despite the severity and chronicity of this problem, there is little research to guide the development of new physical therapy interventions for IAT.

Tendon degeneration results in altered tendon characteristics (shape, composition) in persons with IAT. A larger diameter and lower echogenicity at the tendon insertion are due to the loss of parallel collagen structure, loss of fiber integrity, fatty infiltration, and/or capillary proliferation.^{6,9,19} Ultrasound imaging is a valid, reliable, and sensitive tool to detect altered tendon characteristics due to tendinopathy.^{6,10,31} Aström and colleagues⁶ demonstrated that tendon thickness, measured both by ultrasound ($r = 0.51$) and magnetic resonance imaging (MRI) ($r = 0.49$), correlated with the histopathological score of Achilles tendon pathology in midportion and insertional Achilles tendinopathy. Additionally, Collinger and colleagues⁹ demonstrated that a darker tendon on ultrasound imaging (ie, lower echogenicity) indicated altered tendon composition in persons with rotator cuff tendinopathy compared to healthy con-

● **STUDY DESIGN:** Case-control laboratory study.

● **OBJECTIVES:** To compare tendon characteristics (shape, composition) and mechanical properties (strain, stiffness) on the involved side of participants with insertional Achilles tendinopathy (IAT) to the uninvolved side and to controls, and to examine if severity of tendon pathology is associated with severity of symptoms during function.

● **BACKGROUND:** Despite the severity and chronicity of IAT, the quality of theoretical evidence available to guide the development of exercise interventions is low. While tendon pathology of midportion Achilles tendinopathy has been described, there are few studies specific to IAT.

● **METHODS:** Twenty individuals with unilateral IAT and 20 age- and sex-matched controls volunteered to participate. Ultrasound imaging was used to quantify changes in tendon shape (diameter) and composition (echogenicity). A combination of ultrasound and dynamometry was used to measure tendon mechanical properties (strain and stiffness) during passive ankle rotation toward dorsiflexion. Generalized estimating equations were used to examine the association between IAT,

alterations in tendon properties, and participant demographics. Pearson correlation was used to examine the association between severity of tendon pathology and severity of symptoms (Victorian Institute of Sport Assessment-Achilles).

● **RESULTS:** The side with IAT had a larger tendon diameter ($P < .001$), lower echogenicity ($P < .001$), higher strain ($P = .011$), and lower stiffness ($P = .007$) compared to the side without IAT and the controls. On the involved side of participants with IAT, a lower echogenicity correlated with higher severity of symptoms ($r = 0.603$, $P = .010$).

● **CONCLUSION:** Ultrasound imaging combined with dynamometry can discriminate alterations in tendon shape, composition, and mechanics in participants with IAT. Future clinical trials for IAT may consider strategies to alter tendon characteristics and restore tendon mechanics. *J Orthop Sports Phys Ther* 2014;44(9):680-689. Epub 7 August 2014. doi:10.2519/jospt.2014.5369

● **KEY WORDS:** ankle, plantar flexors, tendon, triceps surae, ultrasound

¹Department of Biomedical Engineering, University of Rochester Medical Center, Rochester, NY. ²Department of Orthopaedics and Rehabilitation, University of Rochester Medical Center, Rochester, NY. ³Department of Physical Therapy, Center for Foot and Ankle Research, Ithaca College-Rochester Campus, Rochester, NY. ⁴School of Nursing, University of Rochester, Rochester, NY. ⁵Physical Therapy Program, George Fox University, Newberg, OR. This research was supported by a Sproull Fellowship from the University of Rochester. The protocol for this study was approved by the University of Rochester Research Subjects Review Board and the Ithaca College All-College Review Board for Human Subjects Research. The authors certify that they have no affiliations with or financial involvement in any organization or entity with a direct financial interest in the subject matter or materials discussed in the article. Address correspondence to Dr Ruth Chimenti, University of Rochester, Department of Biomedical Engineering, Goergen Hall 215, Rochester, NY 14642. E-mail: ruth_chimenti@urmc.rochester.edu • Copyright ©2014 *Journal of Orthopaedic & Sports Physical Therapy*®

trols. While these findings support the validity of ultrasound imaging, they are not specific to characterizing tendon alterations in IAT. Moreover, information on tendon characteristics from imaging may have prognostic value.^{4,12,26,35} Nicholson et al²⁶ demonstrated that grading of tendon diameter and severity of altered composition on MRI predicted the success of nonoperative care for IAT. There may be similar value to examining IAT using ultrasound imaging, which has the added benefits of decreased cost and increased availability. However, no studies have examined ultrasound imaging in patients with IAT.

Tendinopathy is associated with changes in mechanical properties of the tendon in patients with midportion Achilles tendinopathy.^{5,8,10,31} However, similar studies of patients with IAT are lacking. The insertional form of Achilles tendinopathy differs from its midportion form, not only in the location of symptoms at the tendon's calcaneal insertion but also in the bony deformity commonly associated with IAT. Approximately 80% of persons with IAT have Haglund's deformity,¹⁶ and more than 70% have calcifications within the tendon.¹⁷ Yet the impact of bony deformity on tendon mechanical properties in persons with IAT is unknown. A combination of ultrasound imaging and isometric dynamometry can capture in vivo Achilles tendon strain, that is, tendon elongation, and stiffness (force required per unit of tendon elongation) during clinically relevant tasks, such as an isometric contraction or a passive stretch.^{5,8,18} Evaluation of mechanical properties has demonstrated increased tendon strain and decreased stiffness in participants with midportion Achilles tendinopathy compared to controls.^{5,8,31} While a similar increase in strain and decrease in stiffness are logically hypothesized in IAT, there is no literature that reports on these factors in patients with IAT.

The quality of evidence guiding exercise interventions for IAT is low, and could be improved with information

TABLE 1		CHARACTERISTICS OF PARTICIPANTS WITH IAT AND MATCHED CONTROL PARTICIPANTS*	
	IAT (n = 20)	Control (n = 20)	P Value
Age, y	58.6 ± 7.8	58.2 ± 8.5	.863
Sex (female), %	55	55	1.00
Weight, kg	87.5 ± 17.5	80.3 ± 16.0	.187
Height, m	1.7 ± 0.1	1.7 ± 0.1	.999
Body mass index, kg/m ²	30.4 ± 5.4	27.9 ± 5.3	.158
VISA-A, %	47.6 ± 26.8	100.0 ± 0.0	.001 [†]
Duration of symptoms, mo [‡]	10 (4-24)	...	NA

Abbreviations: IAT, insertional Achilles tendinopathy; NA, not applicable; VISA-A, Victorian Institute of Sport Assessment-Achilles.
^{*}Values are mean ± SD unless otherwise indicated.
[†]Statistically significant difference (P ≤ .05).
[‡]Values are median (interquartile range).

on the impact of IAT on tendon mechanical properties. Eccentric exercise is commonly prescribed to patients with tendinopathy, based on the high success rate (82%-100%) of the intervention for athletes with midportion Achilles tendinopathy.^{1,11,13,22,27} However, eccentric exercise has been less effective (60% success rate) for sedentary individuals with Achilles tendinopathy,³⁰ and for individuals with IAT (32% or less success rate).^{11,29} While these studies focus on return to the previous level of self-reported function, few studies focus on the mechanical function of the tendon. Arampatzis and colleagues^{2,3} demonstrated that dose-specific isometric exercises increased tendon stiffness in healthy adults. Exercise dose and mode have not been examined in a similar way to determine the effect on tendon mechanical properties in participants with Achilles tendinopathy. Although improvement in tendon mechanical properties is desirable, no literature exists that characterizes in vivo tendon mechanical properties in IAT participants. To investigate the influence of specific exercise dosages on mechanical properties, studies that first establish the mechanical properties of the tendon in participants with pathology and decreased function are needed.

The purpose of this study was to compare tendon characteristics and me-

chanical properties on the involved side of participants with IAT to those of the uninvolved side and to those of age- and sex-matched healthy controls. Similar to participants with midportion Achilles tendinopathy, IAT was hypothesized to be associated with higher measures of pathology in terms of tendon characteristics (greater tendon diameter, abnormal composition) and mechanical properties (greater strain, lower stiffness). Additionally, higher measures of pathology are hypothesized to be associated with greater severity of symptoms in participants with IAT.

METHODS

Participants

TWENTY INDIVIDUALS WITH CHRONIC (greater than 3 months) unilateral IAT and 20 age- and sex-matched controls volunteered to participate. There were no differences in demographic variables between groups (TABLE 1). All participants with IAT were diagnosed by an orthopaedic surgeon and had tenderness to palpation along the distal 2 cm of the Achilles tendon at its insertion. Participants with IAT had chronic symptoms, with a median duration of 10 months (range, 3 months to 15 years), and reported greater symptom severity than controls (TABLE 1). Individuals were excluded if they had a history of foot or ankle surgery, were unable to safely climb stairs indepen-

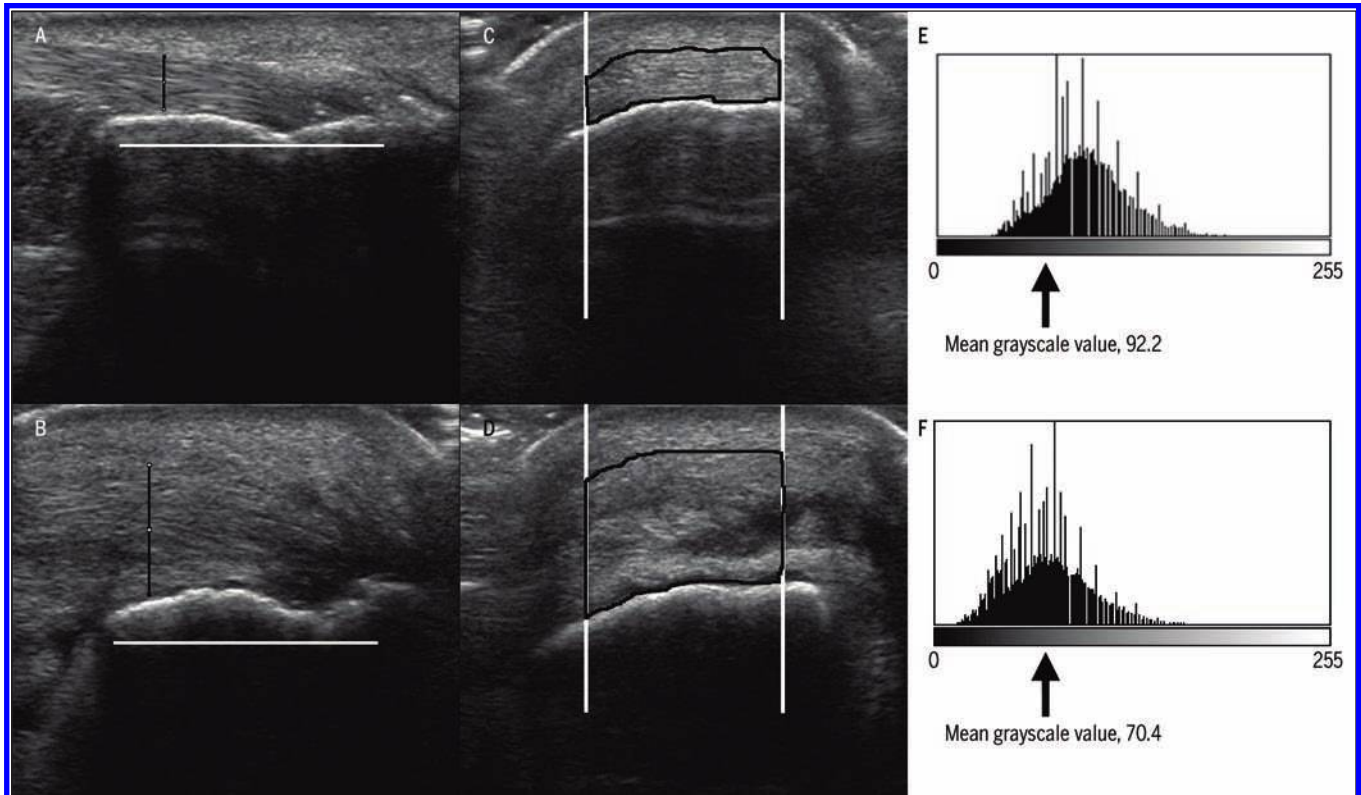


FIGURE 1. Tendon characteristics for uninvolved (top row) and involved (bottom row) sides of a participant with insertional Achilles tendinopathy. (A and B) Longitudinal ultrasound images of tendon diameter; (C and D) cross-sectional ultrasound images of echogenicity measured by the mean grayscale value; (E and F) corresponding histograms demonstrating the mean grayscale value (scale from 0, black to 255, white) for images C and D. A darker tendon results in a lower mean grayscale value, which indicates tendon degeneration.

dently, were pregnant, or had comorbidities that may alter tendon structure (eg, diabetes, neurological condition). The sample size was chosen based on a power analysis, assuming a minimum power of 0.80 and a 2-tailed alpha level of .05. Using a *t* test as a conservative estimate, 16 participants with IAT were needed to detect statistically significant differences between sides for tendon stiffness, based on pilot data indicating a large effect size (Cohen $d = 1$). For a correlational analysis, a sample size of 20 participants with IAT was needed to detect a moderate (0.6 or greater) correlation between tendon characteristics/mechanical properties and symptom severity.

All participants were informed of the study procedures and signed a consent form approved by the University of Rochester Research Subjects Review Board and the Ithaca College All-College Review Board for Human Subjects Research.

Measures

All measures were performed in a single session in the afternoon, as in the morning symptoms are often most severe. Participants were instructed to avoid high-level activities (eg, running, going to the gym) before their session, to minimize the risk that study participation might aggravate their symptoms. Data collection began with motion analysis (a portion of these data were used to measure Achilles tendon moment arm), followed by measurements of tendon characteristics and mechanical properties. Completion of self-report measures and rest periods were interspersed as needed, based on the participant's activity tolerance. The examiners were not blinded to group status (IAT or control) of participants.

Tendon Characteristics

Tendon characteristics (diameter, echogenicity) were measured by obtaining

longitudinal (FIGURES 1A and 1B) and cross-sectional (FIGURES 1C and 1D) images, using B-mode imaging on a Philips HD11 XE digital ultrasound machine (Koninklijke Philips Electronics NV, Amsterdam, the Netherlands) with a linear-array probe (L12-3) at a frequency of 10 to 12 MHz. For these measurements, the participant was in prone and the plantar surface of the foot was stabilized against a board oriented perpendicular to the floor. All ultrasound images were stored digitally and processed using ImageJ (National Institutes of Health, Bethesda, MD). The tendon insertion was defined as the most distal point of the tendon on the calcaneus in a sagittal view. If there were spurs or calcifications in the area of the insertion, the best distal tendon point was estimated. The error in estimating this point in 10 persons with IAT was low (intraclass correlation coefficient [ICC] = 0.981; standard error of measurement [SEM],

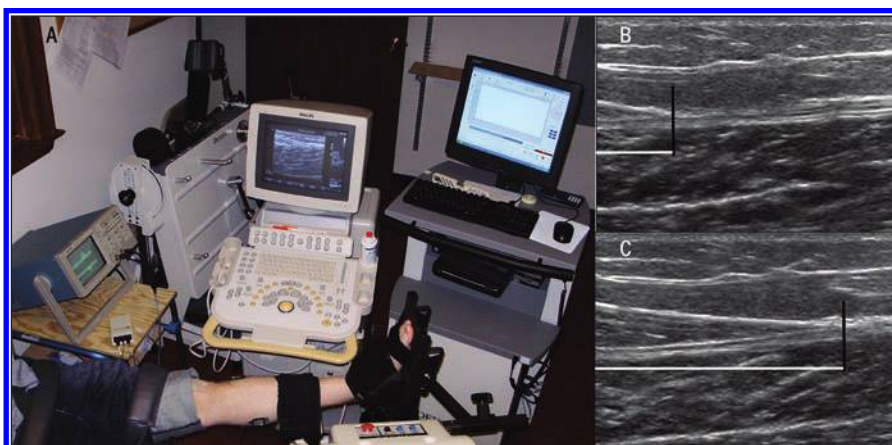


FIGURE 2. (A) Tendon mechanical properties were measured during passive (visually confirmed using electromyography) rotation of the ankle by the isokinetic dynamometer. (B and C) Ultrasound images demonstrating gastrocnemius muscle–Achilles tendon junction displacement as the ankle is rotated from (B) 10° of plantar flexion to (C) 10° of dorsiflexion. The difference in length between the white horizontal lines represents the linear displacement of the muscle-tendon junction during passive ankle rotation.

0.31 mm). On a longitudinal view, tendon diameter was measured at the widest anterior/posterior point within 2 cm of the tendon insertion (FIGURES 1A and 1B). A cross-sectional image was obtained 2 cm proximal to the tendon insertion. Echogenicity was quantified as the mean grayscale value for the central 1 cm of the entire depth of the tendon cross-section (FIGURES 1C and 1D). The grayscale value for a pixel could range from 0 (black) to 255 (white). The mean grayscale value for all pixels in the region of interest was quantified using ImageJ, with a lower value indicating greater pathology. All ultrasound images had the same gain setting of 56 and were collected at a 3-cm depth, so that differences in ultrasound settings would not influence the mean grayscale values between participants.

Tendon Mechanical Properties

The combination of ultrasound imaging and dynamometry was used to measure tendon mechanical properties (strain, stiffness). Each participant's ankle was positioned and secured in a Biodex System 4 (Biodex Medical Systems, Inc, Shirley, NY) in sitting, with the seatback reclined to 45°, the chair height adjusted so that the tibia was parallel to the floor, and the hip in neutral adduction/abduction (FIGURE 2A). The participant's ankle

was moved in the sagittal plane from 10° of plantar flexion to 10° of dorsiflexion at a rate of 5°/s, and the passive plantar flexion torque was recorded at a rate of 1000 Hz. Similar to previous studies,^{5,8,18} ultrasound imaging was used to track the linear displacement of the gastrocnemius muscle–Achilles tendon junction (MTJ), with the probe at a fixed point on the calf (FIGURES 2B and 2C). A first set of 6 rotations was used for preconditioning, followed by a second set of 6 rotations, from which images were used to calculate tendon mechanical properties. B-mode ultrasound images were collected when the ankle was in (1) 10° of plantar flexion at the start and end of the second set and (2) 10° of dorsiflexion during the third, fourth, and fifth repetitions. The location of the MTJ in each ankle position was averaged, so that distance between the MTJ locations in 10° of plantar flexion and 10° of dorsiflexion could be calculated. A video was taken on the second repetition to confirm that the images captured the full range of MTJ displacement. Passive torque values from the third, fourth, and fifth repetitions of the second set were used for analysis.

Participants were instructed to relax as the foot plate moved the ankle. To ensure that the condition was passive, the activity of the medial gastrocnemius and

the anterior tibialis muscles was monitored by a 2-channel Bagnoli desktop electromyography system (Delsys Inc, Natick, MA). Single-differential surface electrodes (input impedance greater than 1015 Ω // 0.2 pF; common-mode rejection ratio, -92 dB; noise, 1.2 μ V; pre-amplifier gain, 10 V/V \pm 1%) were used. The contact material was 99.9% Ag, in the shape of 2 bars with contact dimensions of 10 \times 1 mm and spaced 1 cm apart. The electrodes were placed over the motor point of the medial gastrocnemius and the anterior tibialis muscles. The raw electromyography signal was viewed using a 2-channel digitizing oscilloscope (Tektronix, Inc, Beaverton, OR). The raw data were viewed on the oscilloscope to visually inspect if muscle activity was greater than resting level. If participants had less than 10° of dorsiflexion ($n = 1$) or demonstrated greater than their resting-level muscle activity ($n = 2$), then they were excluded from analysis of tendon mechanical properties.

To calculate tendon strain, tendon elongation was first calculated by subtracting the displacement of the MTJ from the total elongation of the muscle-tendon unit (tendon elongation = total muscle-tendon-unit elongation - muscle elongation). The displacement of the MTJ was recorded using ultrasound imaging. Because the knee joint was immobile, total muscle-tendon-unit elongation was estimated from the change in ankle angle. Previous studies have validated a similar approach to estimating total muscle-tendon-unit elongation.^{14,18} The muscle-tendon-unit elongation also depended on the position of the heel cup on the isokinetic dynamometer, which had 3 adjustments. Depending on the size of the foot, the heel cup was adjusted to approximate the participant's ankle axis of rotation with that of the dynamometer. For each adjustment, the linear translation of the Achilles insertion was established using 3-D motion capture ($n = 3$). A 3-D motion-capture system (Optotrak motion analysis system, model 3020; Northern Digital Inc, Waterloo, On-

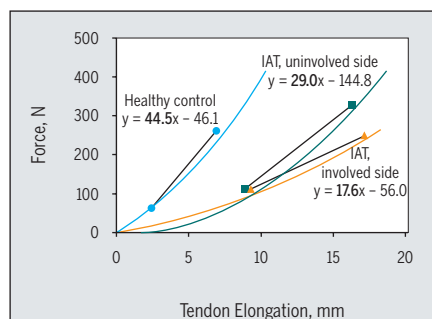


FIGURE 3. Force elongation curve for pilot work in which tendon mechanical properties were examined from 30° of PF to maximum DF. The points on each curve correspond to force and elongation at 10° of DF and 10° of PF (ie, methods used in current study). Stiffness is the slope of the corresponding line highlighted in bold on the linear equations. The curves represent the data for 1 healthy male and 1 male with unilateral IAT. Abbreviations: DF, dorsiflexion; IAT, insertional Achilles tendinopathy; PF, plantar flexion.

tario, Canada) was used to track ankle dorsiflexion at a rate of 60 Hz. Infrared diodes were placed at the tendon insertion and actively emitted light for the cameras to track 3-D motion as the ankle was moved in the sagittal plane. The accuracy of tracking an infrared diode is up to 0.1 mm with the research-grade motion-capture system. After collection, the kinematic data were smoothed using a fourth-order Butterworth filter with a zero phase lag and a cutoff frequency of 6 Hz. Total muscle-tendon-unit elongation was (mean \pm SD) 16.2 \pm 1.9 mm for setting 1, 18.7 \pm 1.1 mm for setting 2, and 19.5 \pm 1.5 mm for setting 3.

Strain was calculated to take into account differences in anthropometrics, with tendon elongation normalized to each individual's tendon length (tendon strain = tendon elongation/tendon length). Two points were used to define the length of the tendon. First, the most distal portion of the tendon insertion was found using ultrasound, and a thin wire was placed under the transducer at the level of the insertion. A mark was made on the skin at the position of the wire. Second, using the same procedure, the medial gastrocnemius MTJ was found using ultrasound and a second mark placed on the skin. The distance between

these 2 points, when the participant was in a prone position with the knee straight and the foot perpendicular to the floor (due to tibial inclination, the ankle was in approximately 10° of plantar flexion), was measured and used as the tendon length. Between-day test-retest reliability of tendon length measurement was good, with an error of \pm 0.04% of original tendon length (n = 6; ICC = 0.910; SEM, 7.9 mm).

To examine the resistance to stretch during passive ankle rotation in dorsiflexion, tendon force was calculated. To derive Achilles tendon force, motion analysis combined with ultrasound imaging was used to estimate Achilles tendon moment arm. In a neutral standing position, for each participant, the medial malleolus and lateral malleolus were digitized, and the center between these 2 points was defined as the ankle joint center. A point was also digitized on the posterior aspect of the heel. The moment arm was calculated by the anterior/posterior distance between the ankle joint center and the digitized heel point (measured with motion capture) minus the anterior/posterior thickness of the skin and subcutaneous tissue (measured with ultrasound imaging). Tendon force was calculated by dividing passive plantar flexion torque (measured by the dynamometer during ankle rotation) by the moment arm of the Achilles tendon (tendon force = passive torque of ankle/moment arm of Achilles tendon). Tendon stiffness was calculated by dividing the change in tendon force by the change in strain as the ankle was rotated from plantar flexion to dorsiflexion (tendon stiffness = change in tendon force/change in tendon strain).

The current study focused on measurement of tendon mechanical properties in the linear region of the force-elongation curve (FIGURE 3). In a previous study by Kawakami et al,¹⁸ the authors measured mechanical properties throughout a greater arc of ankle motion to describe both the toe and linear regions of the force-elongation curve (entire polynomi-

al curve in FIGURE 3). Similar to Kawakami et al,¹⁸ tendon stiffness was approximated using the coefficient of the linear portion of the curve. Because individuals with IAT often experience symptoms during activities that require dorsiflexion,¹⁵ mechanical properties toward the end range of ankle motion, which coincides with the linear portion of the curve, were of particular interest in the current study. An abbreviated 2-point method (point 1, 10° of ankle plantar flexion; point 2, 10° of ankle dorsiflexion) was developed to capture mechanical properties in the linear region of the force-elongation curve (lines connecting 2 points along curves in FIGURE 3). This abbreviated methodology in preliminary work with young, healthy adults was initially compared to the approach described by Kawakami et al.¹⁸ Converting our data into the same units for stiffness reported by Kawakami et al¹⁸ (Nm/%), the average tendon stiffness of young, healthy adults (n = 6; mean \pm SD stiffness, 3.6 \pm 1.6 Nm/%) was within 1 SD of the mean reported by Kawakami et al¹⁸ (3.4 \pm 2.5 Nm/%).

Reliability

Test-retest reliability was examined on different days within the same week. As only 1 physical therapist collected and processed tendon variables, the following statistics represent intrarater reliability. To minimize risk of aggravating symptoms in participants with IAT, repeat testing was performed in 6 young, healthy adults (control participants). Test-retest reliability and SEM for echogenicity (ICC = 0.98; SEM, 3.0 units), diameter (ICC = 0.996; SEM, 0.1 mm), strain (ICC = 0.946; SEM, 0.3%), and stiffness (ICC = 0.998; SEM, 0.7 N/mm) in the control participants were high. A difference between the involved and uninvolved sides greater than 1.96 SEM was used to describe how frequently a comparison between sides indicated altered tendon characteristics on the involved side. This cutoff value was chosen because it represents the 95% confidence interval for a score on the uninvolved side.

In addition, the reliability of processing the ultrasound images was examined. A set of 10 images from the involved and 10 images from the uninvolved sides were blinded. The echogenicity, tendon diameter, and tendon elongation were measured for 20 images twice, and then unblinded and compared for accuracy. The reliability of processed ultrasound images was high ($ICC > 0.9$) for all measures.

Symptom Severity

Symptom severity was measured with the Victorian Institute of Sport Assessment-Achilles questionnaire (VISA-A). This self-report measure sums the score of 8 items to assess stiffness, pain during activity, and ability to participate in sports. The VISA-A has been demonstrated to be a valid, reliable, and sensitive measure in persons with Achilles tendinopathy.^{21,28}

Statistical Analysis

Comparisons between the side with IAT and the side without IAT were tested using generalized estimating equations (GEEs). A GEE analysis uses the generalized linear model, which accounts for the correlation between sides within an individual.³³ This analysis allowed for inclusion of all data (both sides of all participants), and uniquely identified differences between the side with IAT (involved side of participants with IAT, $n = 20$) and the side without IAT (uninvolved side of participants with IAT, $n = 20$; both sides of controls, $n = 40$ sides). Interpretation of the regression coefficients (β) derived from the GEE analysis is similar to standard linear regression. For example, β for the dichotomous independent variable represents, on average, how much greater/lower the side with IAT is compared to the side without IAT. Within the GEE analysis, the significance of the independent variable (side with IAT versus side without IAT) in predicting a dependent variable (echogenicity, diameter, strain, stiffness) was tested using a Wald chi-square test. The GEE

TABLE 2

OUTCOMES OF THE GENERALIZED ESTIMATING EQUATION ANALYSES COMPARING SIDES WITH INSERTIONAL ACHILLES TENDINOPATHY (INVOLVED SIDE) TO SIDES WITHOUT INSERTIONAL ACHILLES TENDINOPATHY (UNINVOLVED SIDE AND CONTROL PARTICIPANTS)

Dependent Variable	β^*	P Value [†]
Diameter, mm	2.5 (1.8, 3.3)	<.001
Echogenicity	-11.2 (-17.1, -5.3)	<.001
Tendon strain, %	1.0 (0.2, 1.7)	.011
Tendon stiffness, N/mm	-12.3 (-21.1, -3.4)	.007

**Values in parentheses are 95% confidence interval.
[†]Statistically significant difference ($P \leq .05$).*

analysis was necessary prior to performing comparisons using the more typical analysis of variance (ANOVA) because of the lack of independence between sides. A significant Wald chi-square test was then followed with an ANOVA to make comparisons across sides and groups. Demographic variables (body mass index, age, sex) were included as covariates in the GEE analyses. Significance was defined as a 2-tailed P value less than or equal to .05.

One-way ANOVAs were used to test whether differences found in the GEE analyses were driven by side (within-subject effect), group (between-subject effect), or both. To test the effect of side, the involved side was compared to the uninvolved side in the participants with IAT. To test the effect of group, the involved side (right or left) in those with IAT was matched for analysis with the corresponding side of an age- and sex-matched control participant. It was hypothesized that the differences between the side with IAT and the side without IAT would be driven by both within- and between-subject effects. If a demographic covariate was statistically significant in the GEE analysis, it was included as a covariate in the ANOVA.

Pearson correlations were used to examine the associations between tendon properties (diameter, echogenicity, strain, stiffness) of the involved side and symptom severity (VISA-A) among par-

ticipants with IAT. Statistical significance for all tests was defined as a 2-tailed P value less than or equal to .05.

RESULTS

THE SIDE WITH IAT HAD ALTERED tendon characteristics (larger tendon diameter and lower echogenicity) compared to the side without IAT. On average, the side with IAT had a 2.5-mm larger tendon diameter and an 11-unit lower echogenicity compared to the side without IAT (**TABLE 2**). These alterations were consistent in pairwise comparisons between sides and between groups. Specifically, the involved side of participants with IAT had a larger tendon diameter than the uninvolved side and the corresponding side in control participants ($P < .001$ between sides and between group comparisons) (**TABLE 3**). Similarly, the involved side had lower echogenicity than the uninvolved side ($P = .002$) and controls ($P = .003$) (**TABLE 3**). A higher body mass index was also associated with a lower echogenicity (GEE analysis: $\beta = -1.9$; 95% confidence interval: $-2.5, -1.3$; $P < .001$; between-side analysis of covariance, $P = .017$; between-group analysis of covariance, $P < .001$). For 85% (17/20) of participants with IAT, the involved side had a larger tendon diameter than the uninvolved side. Compared to the uninvolved side, 65% (13/20) of participants had lower echogenicity on the involved

TABLE 3

PAIRWISE COMPARISONS OF THE INVOLVED SIDE OF PARTICIPANTS WITH IAT TO THE UNINVOLVED SIDE AND TO THE CORRESPONDING SIDE IN MATCHED CONTROLS*

	Participants With Unilateral IAT		
	Involved Side (n = 20 tendons)	Uninvolved Side (n = 20 tendons)	Matched-Control Side (n = 20 tendons)
Diameter, mm	6.4 ± 1.7	4.4 ± 0.7 [†]	3.6 ± 0.7 [†]
Echogenicity	67.3 ± 21.8	77.5 ± 19.0 [†]	84.8 ± 9.6 [†]
Tendon elongation, mm	6.5 ± 2.9	5.2 ± 1.9 [†]	4.5 ± 1.6 [†]
Tendon length, mm	189.8 ± 28.2	189.0 ± 27.3	194.2 ± 23.3
Tendon strain, %	3.4 ± 1.5	2.8 ± 1.0 [†]	2.2 ± 0.6 [†]
Passive force, N	194.9 ± 56.8	206.6 ± 59.6	187.6 ± 48.3
Tendon stiffness, N/mm	33.5 ± 12.6	43.7 ± 19.1 [†]	46.4 ± 20.0 [†]

Abbreviation: IAT, insertional Achilles tendinopathy.

*Values are mean ± SD.

[†]Significant difference ($P \leq .05$) from involved side of participants with IAT with an analysis of variance.

side (difference between sides, greater than 1.96 SEM).

The side with IAT had altered tendon mechanical properties (higher strain and lower stiffness) compared to the side without IAT. The GEE analysis demonstrated that, on average, the side with IAT had a 1% greater strain and a 12-N/mm lower stiffness compared to the side without IAT (TABLE 2). These alterations were consistent in pairwise comparisons between sides and between groups. The involved side in participants with IAT had greater strain than the uninvolved side ($P = .047$) and the corresponding side of participants in the control group ($P = .006$) (TABLE 3). Similarly, the involved side in participants with IAT had lower stiffness than the uninvolved side ($P = .030$) and the corresponding side of those in the control group ($P = .021$) (TABLE 3). There was not sufficient evidence of differences in tendon length (between sides, $P = .349$; between groups, $P = .603$) or tendon force (between sides, $P = .376$; between groups, $P = .677$) in pairwise comparisons (TABLE 3). There were significant differences between sides ($P = .033$) and groups ($P = .020$) in tendon elongation (TABLE 3). Compared to the uninvolved side, 59% (10/17) of participants with

IAT had higher strain on the involved side, and 65% (11/17) of participants had lower stiffness on the involved side compared to the uninvolved side.

On the involved side of participants with IAT, there was a significant association between symptom severity (VISA-A) and tendon characteristics. A lower echogenicity was associated with greater symptom severity ($r = 0.603$, $P = .010$). There was a marginally nonsignificant negative correlation between tendon diameter and symptom severity ($r = -0.456$, $P = .066$). There was no clear evidence of a significant correlation between symptom severity and tendon strain ($r = -0.329$, $P = .197$) or stiffness ($r = 0.165$, $P = .527$).

DISCUSSION

THIS IS THE FIRST STUDY, TO OUR knowledge, to demonstrate that the involved side of individuals with IAT has altered tendon characteristics and mechanical properties, as measured by ultrasound imaging, compared to the contralateral uninvolved side and controls without IAT. Additionally, greater impairment in tendon characteristics (lower echogenicity) on the involved

side was associated with greater symptom severity. Consistent with hypotheses that related IAT to tendon pathology, the involved side of participants with IAT had a larger tendon diameter and lower echogenicity than the uninvolved side and controls. Increased tendon diameter was the most consistent marker of IAT pathology of the ultrasound variables assessed in the current study. Although tendon mechanical properties showed higher strain and lower stiffness, similar to previous studies of midportion Achilles tendinopathy,^{5,8} the clinical significance of the measured changes in mechanical properties requires further study.

Tendon echogenicity is a feasible, quantifiable measure that was associated with the severity of IAT symptoms, as measured by the VISA-A scale. A lower echogenicity (lower mean grayscale value) indicates less organization and homogeneity of the tendon microstructure (greater severity of pathology).⁹ This disorganized microstructure is believed to represent tendon degeneration associated with tendinopathy. However, validity studies connecting histopathology with measures of gray and white pixel patterns from ultrasound imaging (mean grayscale value) would improve the understanding of echogenicity. To date, studies examining the relationship between histopathology and ultrasound measures of tendon composition have been limited by categorical (normal versus abnormal) descriptions of the severity of tendon pathology.^{6,10} However, a categorical measure limits the potential use of echogenicity for diagnostic grading of IAT severity or predicting success with conservative care among a spectrum of patients with IAT. Because echogenicity was associated with body mass index and IAT symptom severity, further studies investigating the relationship between these variables and echogenicity and tendon histopathology are encouraged. Further research is needed to examine why a higher body mass index is associated with a lower echogenicity, and if this may be a risk factor for developing Achilles tendi-

nopathy. In this analysis, body mass index was a covariate, minimizing its influence on the findings of this study.

Tendon diameter was another simple and reliable ultrasound measure that was strongly associated with IAT. In 85% of participants with IAT, ultrasound imaging was sensitive to differences in tendon diameter between the involved and uninjured sides. Given the consistency of this measure to detect differences in diameter, this variable may be particularly useful in the development of prognostic criteria. Nicholson and colleagues²⁶ developed a grading system of tendon pathology using MRI at the Achilles insertion. Participants with a tendon diameter greater than 8 mm and abnormal signal intensity at the insertion were more likely to undergo surgery. For example, 88 of 92 participants with a diameter greater than 8 mm and greater signal abnormality chose surgery. In contrast, participants with a tendon diameter of less than 8 mm and less signal abnormality continued with rehabilitation (2 of 16 participants chose surgery). Ultrasound imaging as performed in the current study may be equally effective in determining prognosis and is much less expensive to employ clinically than MRI. Prognostic information could allow patients to make a more informed choice about their care, when weighing the costs of conservative rehabilitation versus the risks associated with surgical intervention. While prospective data are necessary to establish prognostic factors, this cross-sectional study has established that there is a spectrum of tendon diameter thickness across participants with IAT.

Insertional and midportion Achilles tendinopathies may both have similar effects on tendon strain. The current study found a difference in strain (1.2%) between participants with IAT and controls that was similar in magnitude to that of previous studies comparing participants with midportion Achilles tendinopathy to controls (Arya and Kulig,⁵ 0.8%; Child et al,⁸ 1.8%). Methodological differences, such as a passive or active task,³² range

of ankle excursion,¹⁸ and determining the tendon length,⁷ can affect values when comparing across studies. For example, it would be anticipated that during an isometric contraction, as performed in the studies of Arya and Kulig⁵ and Child et al,⁸ the strain would be greater than during a passive task,³² as performed in the current study. Nonetheless, the similar group effects across different methodologies and types of Achilles tendinopathy support the idea that tendon strain is increased in this population. While these between-group differences in strain appear relatively small, the magnitude of the difference may increase with dynamic tasks, such as running, stair climbing, or end-range calf stretches. For example, the strain associated with single-leg hopping (Lichtwark and Wilson,²⁰ 8.3%) is nearly 4 times the amount of strain demonstrated by controls for the current study during a 20° passive ankle dorsiflexion movement (2.2%) (TABLE 3). Alterations in strain during more challenging tasks may affect dynamic muscle-tendon function. Although a link between tendon mechanical properties and muscle-tendon function is possible, no evidence of this relationship between strain and symptom severity ($r = -0.329$, $P = .197$) was found in the current study.

Based on the results of this study, the use of passive stretching of the Achilles tendon as part of a conservative treatment program for IAT is inconsistent with the finding of higher tendon strain. The finding of excessive elongation of the Achilles tendon calls into question the regular administration of calf stretching for tendons that already exhibit increased strain. Although commonly recommended, based on anecdotal experience, there is little empirical evidence to support stretching in patients with IAT.³⁴ Typically, the goal of calf stretching is to increase dorsiflexion range of motion. Stretching the calf muscle also may increase strain of the Achilles tendon. Data from the current study demonstrate that strain is typically increased, not decreased, in participants with IAT. Further studies of the

influence of dorsiflexion range of motion, Achilles tendon strain, and its influence on continuing symptoms associated with IAT are necessary.

Despite some differences in methods and type of tendon problems across studies, the effect of tendinopathy on stiffness was similar to that reported in other studies. The current study examined tendon stiffness during a passive task (20° ankle rotation toward dorsiflexion) and found a 27.8% decrease in tendon stiffness in participants with IAT compared to controls. Similarly, during an active task (maximum voluntary isometric contraction), Arya and Kulig⁵ found a 24.9% decrease in Achilles tendon stiffness in participants with midportion Achilles tendinopathy. A passive task was chosen for the current study to obtain similar loading between the IAT and control groups. Yet, individuals with IAT may show greater differences in tendon characteristics under higher loads. Stiffness in participants with IAT may also be assessed with an active test in which stiffness is measured during a maximal isometric effort. This was not done in the current study, because differences in strength would have confounded the comparison between groups (tendon strain is not independent from force). Future studies, however, may consider using various submaximal loads to evaluate tendon stiffness under more functional loading conditions.

Therapeutic strategies designed to reverse alterations in mechanical properties may improve clinical outcomes for IAT. Although eccentric exercise is commonly prescribed for IAT,^{11,16,29} in controls, isometric exercise stimulated improvement in tendon mechanical properties. Two studies of healthy participants have demonstrated increased Achilles tendon stiffness after a 14-week isometric exercise training protocol.^{2,3} Conversely, studies demonstrating the effect of eccentric exercise at 6 weeks showed a decrease in Achilles tendon stiffness.^{23,25} To date, research on the effects of exercise on Achilles tendon mechanical properties has been limited to a healthy population. The

ability of exercise to alter the tendon mechanical properties of participants with tendinopathy remains unexplored. Theoretically, common exercises for Achilles tendinopathy, such as calf stretching and eccentric exercise, may promote increased tendon strain and decreased stiffness. Given that half of people with IAT progress to surgical care,²⁶ current conservative care should be re-evaluated. An intervention that improves tendon mechanical properties and reduces pain may substantially improve the prognosis for patients with IAT. This study documents increased strain and reduced stiffness in persons with IAT, which could be used for planning clinical trials of exercise that integrate measures of tendon mechanical properties and pain responses.

One limitation of the current study is that not all participants were able to complete the protocol for testing tendon mechanical properties. The current method involved rotating the ankle to 10° of dorsiflexion, because it was near end range yet also comfortable for pilot subjects with IAT. However, 1 participant in the current study was unable to achieve 10° of dorsiflexion, and 2 others had difficulty relaxing throughout this motion. Methods that examine mechanical properties throughout the individual's available dorsiflexion motion, as done by Kawakami et al,¹⁸ may take more time for data collection but could reduce the amount of missing data due to limited ankle dorsiflexion. Another limitation is that tendon mechanical properties were of the entire tendon, rather than locally measured at the tendon insertion. Because the tendon functions as a unit during exercise and daily activities, the current findings are clinically applicable. However, development of methodology specific to the tendon insertion may have greater sensitivity to detect abnormal mechanical properties among individuals with IAT. Another limitation is that estimates of tendon elongation are difficult. Error in measuring tendon elongation could result from poor stabilization of the foot in the heel cup of the isokinetic

device and/or skin artifact. These potential errors were minimized in the current study by examining tendon mechanical properties over a relatively small range of motion.

CONCLUSION

THIS STUDY CONFIRMS THAT ULTRASOUND imaging is able to characterize changes in tendon shape and composition in persons with IAT. To our knowledge, this is the first study to demonstrate that alterations in tendon mechanical properties are associated with IAT. This is consistent with previous studies documenting abnormal tendon characteristics and mechanical properties in participants with midportion Achilles tendinopathy. Further, the association of tendon composition and symptom severity may indicate the clinical relevance of tendon pathology for functional recovery. Future clinical trials may consider strategies to alter tendon composition and restore tendon mechanics in participants with IAT. ●

KEY POINTS

FINDINGS: Tendon characteristics (increased diameter and lower echogenicity) acquired with ultrasound imaging were altered in persons with IAT. Further, greater impairment in tendon characteristics was associated with greater symptom severity. The side with IAT had altered tendon mechanical properties (greater tendon strain and lower stiffness) compared to the side without IAT.

IMPLICATIONS: Although prospective research is needed, ultrasound imaging is promising as a clinical measure of IAT severity. Altered tendon mechanical properties support the rationale for exercise interventions that increase tendon stiffness and potentially reverse IAT-related changes within the tendon.

CAUTION: More research is needed to evaluate and develop the clinical utility of ultrasound imaging for use with individual patients.

ACKNOWLEDGEMENTS: We thank Deborah Nawoczenski, PT, PhD for her contribution to this work as a member of Dr Chimenti's dissertation committee, and the Foundation for Physical Therapy in the awarding of a 2012 Kendall Scholarship to Dr Chimenti at the beginning of her doctoral work.

REFERENCES

1. Alfredson H, Pietilä T, Jonsson P, Lorentzon R. Heavy-load eccentric calf muscle training for the treatment of chronic Achilles tendinosis. *Am J Sports Med.* 1998;26:360-366.
2. Arampatzis A, Karamanidis K, Albracht K. Adaptational responses of the human Achilles tendon by modulation of the applied cyclic strain magnitude. *J Exp Biol.* 2007;210:2743-2753. <http://dx.doi.org/10.1242/jeb.003814>
3. Arampatzis A, Peper A, Bierbaum S, Albracht K. Plasticity of human Achilles tendon mechanical and morphological properties in response to cyclic strain. *J Biomech.* 2010;43:3073-3079. <http://dx.doi.org/10.1016/j.jbiomech.2010.08.014>
4. Archambault JM, Wiley JP, Bray RC, Verhoeve M, Wiseman DA, Elliott PD. Can sonography predict the outcome in patients with achillogynia? *J Clin Ultrasound.* 1998;26:335-339. [http://dx.doi.org/10.1002/\(SICI\)1097-0096\(199809\)26:7<335::AID-JCU1>3.0.CO;2-A](http://dx.doi.org/10.1002/(SICI)1097-0096(199809)26:7<335::AID-JCU1>3.0.CO;2-A)
5. Arya S, Kulig K. Tendinopathy alters mechanical and material properties of the Achilles tendon. *J Appl Physiol (1985).* 2010;108:670-675. <http://dx.doi.org/10.1152/jappphysiol.00259.2009>
6. Aström M, Gentz CF, Nilsson P, Rausing A, Sjöberg S, Westlin N. Imaging in chronic Achilles tendinopathy: a comparison of ultrasonography, magnetic resonance imaging and surgical findings in 27 histologically verified cases. *Skeletal Radiol.* 1996;25:615-620.
7. Carmont MR, Silbernagel KG, Mathy A, Mulji Y, Karlsson J, Maffulli N. Reliability of Achilles tendon resting angle and calf circumference measurement techniques. *Foot Ankle Surg.* 2013;19:245-249. <http://dx.doi.org/10.1016/j.fas.2013.06.007>
8. Child S, Bryant AL, Clark RA, Crossley KM. Mechanical properties of the Achilles tendon aponeurosis are altered in athletes with Achilles tendinopathy. *Am J Sports Med.* 2010;38:1885-1893. <http://dx.doi.org/10.1177/0363546510366234>
9. Collinger JL, Fullerton B, Impink BG, Koontz AM, Boninger ML. Validation of grayscale-based quantitative ultrasound in manual wheelchair users: relationship to established clinical measures of shoulder pathology. *Am J Phys Med Rehabil.* 2010;89:390-400. <http://dx.doi.org/10.1097/PHM.0b013e3181d8a238>

10. De Zordo T, Chhem R, Smekal V, et al. Real-time sonoelastography: findings in patients with symptomatic Achilles tendons and comparison to healthy volunteers. *Ultraschall Med.* 2010;31:394-400. <http://dx.doi.org/10.1055/s-0028-1109809>
11. Fahlström M, Jonsson P, Lorentzon R, Alfredson H. Chronic Achilles tendon pain treated with eccentric calf-muscle training. *Knee Surg Sports Traumatol Arthrosc.* 2003;11:327-333. <http://dx.doi.org/10.1007/s00167-003-0418-z>
12. Fredberg U, Bolvig L. Significance of ultrasonographically detected asymptomatic tendinosis in the patellar and Achilles tendons of elite soccer players: a longitudinal study. *Am J Sports Med.* 2002;30:488-491.
13. Gardin A, Movin T, Svensson L, Shalabi A. The long-term clinical and MRI results following eccentric calf muscle training in chronic Achilles tendinosis. *Skeletal Radiol.* 2010;39:435-442. <http://dx.doi.org/10.1007/s00256-009-0798-3>
14. Grieve DW, Pheasant S, Cavanagh PR. Prediction of gastrocnemius length from knee and ankle joint posture. In: Asmussen E, Jørgensen K, eds. *Biomechanics VI-A*. Baltimore, MD: University Park Press; 1978:405-413.
15. Johnson KW, Zalavras C, Thordarson DB. Surgical management of insertional calcific Achilles tendinosis with a central tendon splitting approach. *Foot Ankle Int.* 2006;27:245-250.
16. Jonsson P, Alfredson H, Sunding K, Fahlström M, Cook J. New regimen for eccentric calf-muscle training in patients with chronic insertional Achilles tendinopathy: results of a pilot study. *Br J Sports Med.* 2008;42:746-749. <http://dx.doi.org/10.1136/bjism.2007.039545>
17. Kang S, Thordarson DB, Charlton TP. Insertional Achilles tendinitis and Haglund's deformity. *Foot Ankle Int.* 2012;33:487-491. <http://dx.doi.org/10.3113/FAI.2012.0487>
18. Kawakami Y, Kanehisa H, Fukunaga T. The relationship between passive ankle plantar flexion joint torque and gastrocnemius muscle and Achilles tendon stiffness: implications for flexibility. *J Orthop Sports Phys Ther.* 2008;38:269-276. <http://dx.doi.org/10.2519/jospt.2008.2632>
19. Klauser AS, Miyamoto H, Tamegger M, et al. Achilles tendon assessed with sonoelastography: histologic agreement. *Radiology.* 2013;267:837-842. <http://dx.doi.org/10.1148/radiol.13121936>
20. Lichtwark GA, Wilson AM. In vivo mechanical properties of the human Achilles tendon during one-legged hopping. *J Exp Biol.* 2005;208:4715-4725. <http://dx.doi.org/10.1242/jeb.01950>
21. Maffulli N, Testa V, Capasso G, Sullo A. Calcific insertional Achilles tendinopathy: reattachment with bone anchors. *Am J Sports Med.* 2004;32:174-182.
22. Mafi N, Lorentzon R, Alfredson H. Superior short-term results with eccentric calf muscle training compared to concentric training in a randomized prospective multicenter study on patients with chronic Achilles tendinosis. *Knee Surg Sports Traumatol Arthrosc.* 2001;9:42-47.
23. Mahieu NN, McNair P, Cools A, D'Haen C, Vandermeulen K, Witvrouw E. Effect of eccentric training on the plantar flexor muscle-tendon tissue properties. *Med Sci Sports Exerc.* 2008;40:117-123. <http://dx.doi.org/10.1249/mss.0b013e3181599254>
24. McGarvey WC, Palumbo RC, Baxter DE, Leibman BD. Insertional Achilles tendinosis: surgical treatment through a central tendon splitting approach. *Foot Ankle Int.* 2002;23:19-25.
25. Morrissey D, Roskilly A, Twycross-Lewis R, et al. The effect of eccentric and concentric calf muscle training on Achilles tendon stiffness. *Clin Rehabil.* 2011;25:238-247. <http://dx.doi.org/10.1177/0269215510382600>
26. Nicholson CW, Berlet GC, Lee TH. Prediction of the success of nonoperative treatment of insertional Achilles tendinosis based on MRI. *Foot Ankle Int.* 2007;28:472-477. <http://dx.doi.org/10.3113/FAI.2007.0472>
27. Öhberg L, Lorentzon R, Alfredson H. Eccentric training in patients with chronic Achilles tendinosis: normalised tendon structure and decreased thickness at follow up. *Br J Sports Med.* 2004;38:8-11; discussion 11. <http://dx.doi.org/10.1136/bjism.2001.000284>
28. Robinson JM, Cook JL, Purdam C, et al. The VISA-A questionnaire: a valid and reliable index of the clinical severity of Achilles tendinopathy. *Br J Sports Med.* 2001;35:335-341.
29. Rompe JD, Furia J, Maffulli N. Eccentric loading versus eccentric loading plus shock-wave treatment for midportion Achilles tendinopathy: a randomized controlled trial. *Am J Sports Med.* 2009;37:463-470. <http://dx.doi.org/10.1177/0363546508326983>
30. Sayana MK, Maffulli N. Eccentric calf muscle training in non-athletic patients with Achilles tendinopathy. *J Sci Med Sport.* 2007;10:52-58. <http://dx.doi.org/10.1016/j.jsams.2006.05.008>
31. Sconfienza LM, Silvestri E, Cimmino MA. Sonoelastography in the evaluation of painful Achilles tendon in amateur athletes. *Clin Exp Rheumatol.* 2010;28:373-378.
32. Theis N, Mohagheghi AA, Korff T. Method and strain rate dependence of Achilles tendon stiffness. *J Electromyogr Kinesiol.* 2012;22:947-953. <http://dx.doi.org/10.1016/j.jelekin.2012.06.004>
33. Twisk JWR. *Applied Longitudinal Data Analysis for Epidemiology: A Practical Guide*. New York, NY: Cambridge University Press; 2003.
34. Verrall G, Schofield S, Brustad T. Chronic Achilles tendinopathy treated with eccentric stretching program. *Foot Ankle Int.* 2011;32:843-849. <http://dx.doi.org/10.3113/FAI.2011.0843>
35. Zanetti M, Metzendorf A, Kundert HP, et al. Achilles tendons: clinical relevance of neovascularization diagnosed with power Doppler US. *Radiology.* 2003;227:556-560. <http://dx.doi.org/10.1148/radiol.2272012069>